

See discussions, stats, and author profiles for this publication at: <https://www.researchgate.net/publication/51920255>

Median Frontal Sutures – Incidence, Morphology and Their Surgical, Radiological Importance

Article in *Turkish Neurosurgery* · October 2011

DOI: 10.5137/1019-5149.JTN.4293-11.0 · Source: PubMed

CITATIONS

30

READS

447

6 authors, including:



Murlimanju Bv

Manipal Academy of Higher Education

156 PUBLICATIONS 1,371 CITATIONS

SEE PROFILE



Manohar Varadaraya Pai

Manipal Academy of Higher Education

94 PUBLICATIONS 1,430 CITATIONS

SEE PROFILE



Simesh M.s.

14 PUBLICATIONS 254 CITATIONS

SEE PROFILE

Median Frontal Sutures – Incidence, Morphology and Their Surgical, Radiological Importance

Medyan Frontal Sütür – İnsidansı, Morfoloji ve Cerrahi, Radyolojik Önemi

B.V. MURLIMANJU¹, Latha V. PRABHU¹, Mangala M. PAI¹, Avlyn Anisha GOVEAS¹, K.V.N. DHANANJAYA², M.S. SOMESH³

¹Manipal University, Kasturba Medical College, Department of Anatomy, Mangalore (D.K.), India

²Manipal University, Kasturba Medical College, Department of Radiology, Mangalore (D.K.), India

³Sri Sreenivas Institute of Medical Sciences and Research, Department of Anatomy, Mukka, Mangalore (D.K.), India.

Presented in: A report of this investigation has been read at the 58th National Conference of the Anatomical Society of India which was held at Pune, India from 27th to 29th December, 2010.

Correspondence address: B.V. MURLIMANJU / E-mail: flutesnowmm@gmail.com

ABSTRACT

AIM: To determine the incidence of metopic suture in Indian human adult skulls and to study their morphology.

MATERIAL and METHODS: The study included 81 human adult dry skulls which were obtained from the neuroanatomy laboratory of our institution. The skulls were macroscopically inspected at the norma frontalis for the presence of the metopic suture and the sutures were morphologically analyzed. The sutures were classified as complete and incomplete types. The incomplete ones included linear type, 'V' shape and double type.

RESULTS: From our observations, the metopic suture was present in 52 (64.1%) cases. The complete metopic suture was seen in only 1 skull (1.2%). The majority of the metopics were of incomplete type, 51 (62.9%). Among the incomplete ones, 18 (22.2%) were linear, 17 (21%) were 'V' shaped and 16 were double metopics (19.7%). No metopic sutures were associated with the Wormian bones.

CONCLUSION: The morphological knowledge of the metopic suture is important for the radiologists and neurosurgeons in day to day practice. While reading the X-ray / CT and MRI films, the possibility of the metopic suture should be kept in mind. This will prevent confusion and a wrong diagnosis in emergency situations.

KEYWORDS: Frontal bone, Metopic, Metopism, Morphology, Skull, Suture

ÖZ

AMAÇ: Hint insan erişkin kafatasında metopik eklem (sütür) sıklığını belirlemek ve yapısal özelliklerini incelemek.

YÖNTEM ve GEREÇLER: Üniversitemiz nöroanatomisi laboratuvarında elde edilen 81 yetişkin insan kafatası metopik eklemi incelenmiştir. Kafatasları makroskopik olarak metopik eklem açısından kontrol edildi. Metopik Sütür tam eklem ve eksik tip olmak üzere iki temel gruba ayrıldı; eksik olan grup ise 3 alt gruba ayrıldı. Bunlar, Çizgisel tip, 'V' şeklinde olan ve ikili metopik eklem idi.

BULGULAR: Metopik sütür (eklem) 52 (%64,1), tam metopik sütür 1 kafatasında (%1,2) görüldü. Metopik eklemlerin çoğunluğunda tam olmayan tip saptandı. Örneklerin 51'inde (%62,9). tam olmayan metopik eklem saptandı. Tam olmayanlardan 18'i (%22,2) çizgisel, 17'si (% 21) 'V' şeklinde ve 16 çift metopik eklem (%19,7) bulundu. Vormian kemikle ilişkili olan metopik eklem rastlanmamıştır.

SONUÇ: Metopik eklem yapısal bilgisi radyologlar ve beyin cerrahları için önemli bir detay olarak görülmelidir. BT, manyetik rezonans görüntüleri ve direkt x ray grafileri okunurken metopik eklem olasılığı akılda tutulmalıdır. Bu yaklaşım acil durumlarda hastalara yanlış tanı konmasını ve karışıklık oluşmasını önleyecektir.

ANAHTAR SÖZCÜKLER: Frontal kemik, Metopik, Metopism, Morfoloji, Kafatası, Kafatası eklemi

INTRODUCTION

Metopism, which is defined as a condition in which the two pieces of the frontal bone fail to merge in early childhood, displays varying degrees of incidence (12). The metopic sutures are vertical sutures occurring as a result of failure of ossification between the two halves of frontal bone. It was described that the obliteration of metopic sutures begins

at the level of frontal tuber and extends both upwards and downwards, and sometimes traces may be left either at the bregma or nasion if the fusion is not complete (20). When the metopic sutures are complete and extend from nasion to bregma, the condition is called as metopism (5). If the suture is not present throughout and occupies a small area between these two points, they are considered as incomplete metopic sutures. They are also called as median frontal sutures and

usually present between the two super ciliary arches. They may be found associated with the Wormian bones. It was reported that these sutures may be misdiagnosed as vertical traumatic skull fractures extending in the mid-line in head injury patients (4). It was reported that the time of physiological closure of these sutures varies from birth to 8 years of age, the widely accepted closing period has been approximated at 2 years of age (4). Caffey (8) described that these sutures might persist throughout the life in about 10% of the cases. Many authors report that there exists a racial variability among the incidence of metopic sutures (2). Their incidence was 7-8% in Europeans, 1% in Africans and 4-5% in Mongolian population. The frequency may range from 1% to 12% and the incidence is slightly higher in the male population (15). In a study by Hanihara et al. (14), it was observed that the cranial traits show distinctive patterns of geographic variations. In the present study, the objectives were to determine the incidence of metopic sutures in Indian human adult skulls and to study their morphology.

MATERIAL and METHODS

The study included 81 (52 males and 29 females) human adult dry skulls which were obtained from the neuroanatomy laboratory of our institution. The skulls were differentiated into males and females based on the criteria of sexual dimorphism which is explained in the standard anatomy and forensic medicine text books. Skulls that had visible deformities and were damaged were excluded from the present study. The skulls were macroscopically inspected at the norma frontalis for the presence of the metopic suture. The sutures were classified as complete and incomplete. A suture which is found completely between the bregma and nasion is termed as the complete metopic suture or metopism. If it extends to a smaller distance either from the bregma or from the nasion, it is termed as incomplete type. The incomplete ones included linear type, 'V' shape and double type. The method of classification of the metopic sutures is based on the reports of Agarwal et al. (1), Ajmani et al. (2) and Castilho et al. (9). The incidence of complete and incomplete metopics were calculated, the data obtained were compared with those from earlier studies.

RESULTS

The metopic suture was present in 52 (64.1%) cases. Among them 40 (76.9%) were seen in men and 12 (23.1%) in women. The majority of metopics were of incomplete type (Figure 1), seen in 51 skulls (63%) and only one male skull had the complete metopic suture (1.2%) (Figure 2A). Among the incomplete ones, 18 (22.2%) were linear (Figure 1A), 17 (21%) were 'V' shaped (Figure 1B) and 16 skulls had double metopic (Figure 1C) sutures (19.7%). The remaining 35.9% of the skulls did not show a metopic suture (Figure 1D). The morphological distribution of the metopic sutures of the present study is represented in Figure 3. The other morphological types like 'U' shape, 'H' shape and 'N' were not found in the present study. No metopic sutures were associated with the Wormian bones. The frequency, number of complete and each incomplete

metopic suture shape with respect to gender is presented in Table I. The data as compared with previous studies and the racial variability of the metopism is shown in Table II.

DISCUSSION

Metopic suture is a kind of dentate suture (2), which runs between the frontal bones of the fetus, from the ventral part of the anterior fontanelle to the nasion. It is considered to be an anterior extension of the sagittal suture (15). The etiology of persistent metopic suture is as unclear as why it demonstrates synostosis (4). During fetal life, the two frontal bones are separated by the sutural space which consists of fibrous tissue and mesenchymal cells. These cells are believed to be responsible for the growth of frontal bones and this mesenchyme differentiates either into bone or cartilage (19). It has been stated that the metopic sutures increase the width of the skull (6). Manzaranes et al. (18) suggested that chondroid tissue is responsible for suture closure and maintenance of an open suture occurs by the process of active resorption. They reported that the open statuses of the sutures are maintained by the osteoclastic resorption. Levine (17) from his animal models discussed the role of the dura mater-suture complex in determining metopic suture patency. It was indicated that some cytokines showed increased expression during active cranial suture fusion (4).

The metopic suture normally closes between the ages of 1st to 2nd year and is usually fused completely by the 3rd year, but it can remain patent up to the 7th year (15). However the closure of rest of the cranial sutures in man occurs between 26 and 30 yrs, with subsidiary periods of activity from 50 to 70 yrs (18). In comparative anatomy, it was described that

Table I: Frequency and Number of Each Metopic Suture Shape with Respect to Gender

Shape	Male	Female	Total
Complete	1 (1.9%)	nil	1 (1.2%)
Incomplete	39 (75%)	12 (41.4%)	51 (63%)
Linear	9 (17.4%)	9 (31%)	18 (22.2%)
V	15 (28.8%)	2 (7%)	17 (21%)
Double	15 (28.8%)	1 (3.4%)	16 (19.7%)

Table II: Racial Variations in the Incidence of Metopism

Authors	Population	Incidence (%)
Bryce (1915)	Scottish	9.5
Bryce (1915)	Australian	1
Bryce (1915)	Mongolian	5.1
Bryce (1915)	European	8.7
Ajmani et al. (1983)	Nigerian	3.4
Bilodi et al. (2003)	Nepalese	3.92
Baaten et al. (2003)	Lebanese	0.82
Castilho et al. (2006)	Brazilian	7.4
Present study (2010)	Indian	1.2

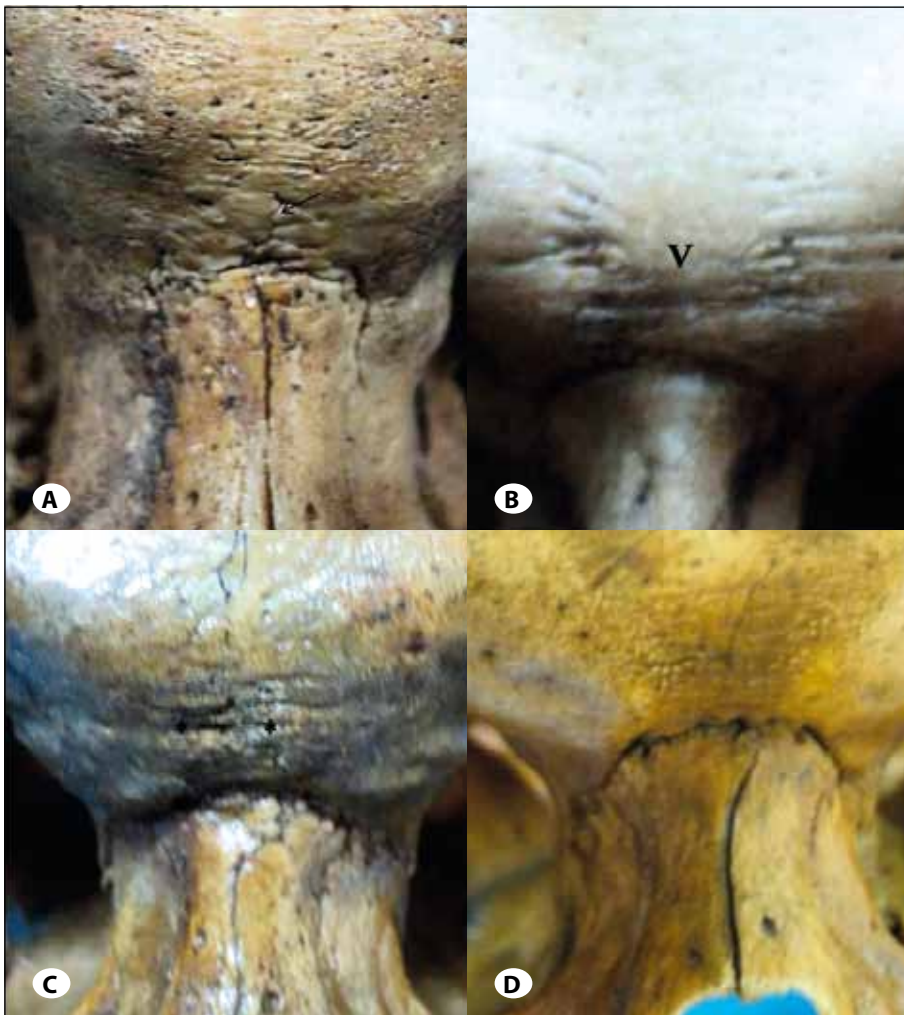


Figure 1: Morphological variants of incomplete metopic sutures, **A)** linear type (arrow mark), **B)** 'V' shape, **C)** double type (*), **D)** absent metopic suture.

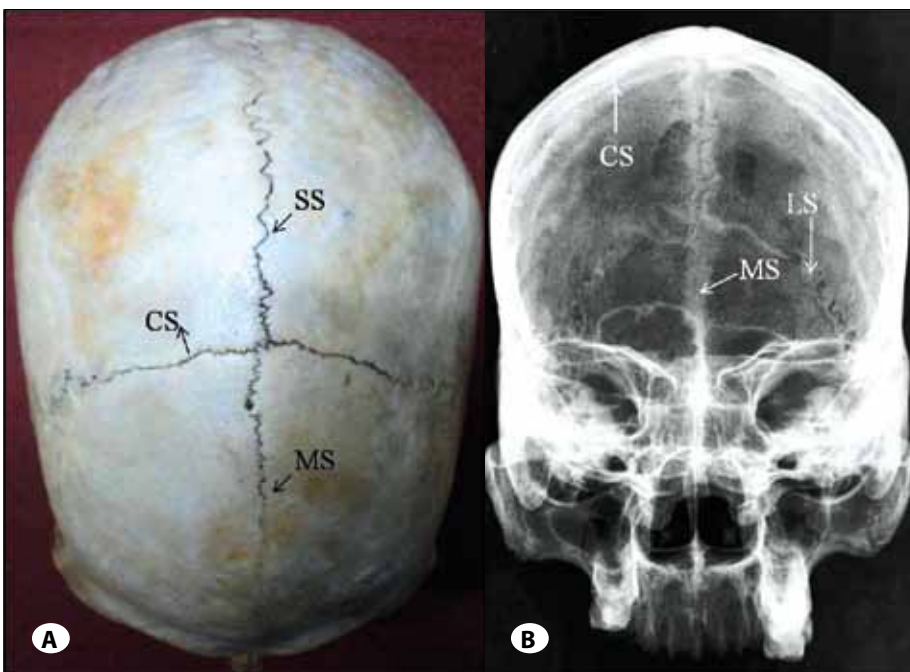


Figure 2: **A)** Superior view of the skull showing the metopism, **B)** Anteroposterior radiograph of the skull showing the complete metopic suture. (CS – coronal suture, SS – sagittal suture, LS – lambdoid suture, MS – metopic suture).

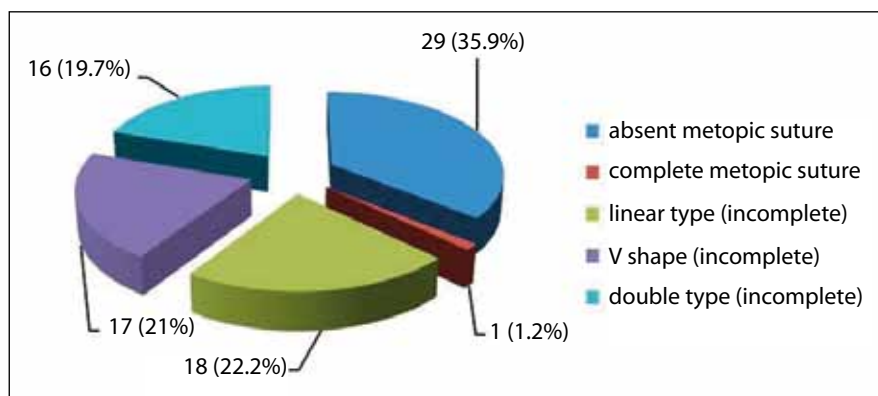


Figure 3: Morphological distribution of the metopic sutures in Indian skulls (n=82).

the closure of metopic sutures happens at the time of loss of deciduous teeth in monkeys (10). Jit and Banga (16) explained that persistence of the metopic suture does not affect the cranial shape. But Skrzat et al. (15) opined that, debate exists whether the shape of metopic skulls differs from those of non-metopic skulls. They concluded that it remains difficult to answer as there is a lack of suitable data on this subject. Though the metopic sutures are rare to find in adults, are not considered as pathological (15). But their premature fusion can result in craniosynostosis and trigonocephaly (22) and is termed as metopic synostosis. Bryce (7) stated that the metopism is more frequent in the taller individuals.

Vu et al. (21) from their radiological study opined that the metopic fusion may normally occur as early as 3 months of age and complete fusion occurs by 9 months. They explained that, in some cases metopic suture persists as an incomplete or complete suture extending from nasion to the anterior angle of bregma and the condition is called metopism or sutura frontalis persistens. According to del Sol et al. (11), the causative factors of metopism include the abnormal growth of cranial bones, hydrocephalus, growth retardation, sexual influence, heredity, atavism, stenocrotaphia (abnormal narrowing of the temporal area of the head), plagiocephaly (cranial malformation causing a twisted and asymmetrical head because of the synostosis of the cranial sutures), scaphocephaly (deformed head, projecting forward like the keel of a boat), mechanical causes and hormonal dysfunction. The genetic influence is the most currently accepted factor among the scientific community (9). It was reported that the impaired closure of the metopic suture is common in Apert syndrome (13).

In the present study, the metopic sutures were observed in 64.1% of the skulls. Among them 40 (76.9%) were seen in male and 12 (23.1%) in females. Similar male preponderance of metopic sutures was observed earlier by Baaten et al. (3). But Castilho et al. (9) reported the female preponderance of metopic sutures. They observed the occurrence of metopism in 7.04% of the skulls, of which 80% were female and 20% male. The incomplete metopic sutures were found in 32.39%, with higher frequency in females, 60.86%, when compared to the males that reached 31.13%. In the present study, only one male skull showed the complete metopic suture (metopism,

Figure 2A), the incidence rate of metopism was determined as 1.2%. According to del Sol et al. (11) in 400 skulls of Brazilians, the incidence of metopism found was of 2.75%. The highest incidence of metopism was reported in Alpine skulls as 63.2% (11) and the lowest was described in Australian and Scottish skulls, 1% (7). On the other hand, the smaller incidences were reported among black population (2, 7).

In the present study, the majority of the metopics were of incomplete type (Figure 1), seen in 51 skulls (63%). The most common shape was linear (22.2%), which is similar to the previous Indian study by Agarwal et al. (1). They observed this type of suture in 23.12% of the cases. Our finding is also similar to the incidence of 24.27% from a Nigerian study by Ajmani et al. (2). But our incidence rate is different from those in other races by Castilho et al. (9), 69.57% and del Sol et al. (11), 64.35%. In our study, the incidence of V shape (21%) was higher to those of Agarwal et al. (1), 3.25% and Ajmani et al. (2) in Nigerian skulls, 0.49%. But this is similar to the report of Castilho et al. (9), they observed the V shape morphology in 17.39% of the cases. The double metopic suture types were observed in 16 (19.7%) of our skulls. In the earlier studies by Agarwal et al. (1), Ajmani et al. (2) and del Sol et al. (11), the other morphological types of incomplete metopic sutures like 'n' shape, 'H' shape and 'U' shape were reported. But in the present study, these variant types were not observed. Few authors reported the presence of Wormian bones in association with the metopic sutures. But these were not found in our series.

It was reported that the incomplete type of metopic sutures are morphologically variable (2). Most of the authors reported that the most commonly observed shape of them was linear type and only in few cases the other forms of suture have been found (15). According to Castilho et al. (9), the linear type being the most frequent, with 69.57% incidence and followed by the V-shape (17.39%) and double shape (13.04%). Ajmani et al. (2) observed the metopism in 3.4% and incomplete metopic sutures in 31.57% of the cases in a study from adult Nigerian skulls. In their study, the most common type of the incomplete metopic suture was the linear (24.27%). In contrast, del Sol et al. (11), reported that incomplete metopic suture existed in 28.75% skulls of Brazilian subjects. Agrawal et al. (1) from a previous Indian study observed the metopism

and incomplete metopic sutures in 2.66% and 38.17% of the cases respectively. According to Baaten et al. (3), the incidence of metopism and incomplete metopic sutures were 0.82% and 0.93% respectively in the Lebanese population. According to them, the incidence was more in rural people compared to those who live in urban areas. In contrast, Bilodi et al. (5) observed the metopic sutures in 11.46 % of their cases, among them the incomplete metopic sutures were 7.84 % and the 3.92% cases were complete metopics. It was reported that the incomplete type of metopic suture shows variations in the superior, middle and inferior part of the frontal bone (2). But we didn't observe any incomplete metopic suture in the upper and middle parts of the frontal bone.

Although the anatomical studies mentioned the persistent metopic suture, it is extremely rare in clinical practice (4). Baaten et al. (3) reported that the incomplete metopic sutures though easily identifiable on the organic piece, are difficult to identify on the X rays and may be mistaken for the vertical fractures close to the central line. In the present study, the radiological appearance of the complete metopic suture is illustrated in Figure 2B. In a head injury patient, there is a chance that the persistent metopic suture may be erroneously interpreted as a vertical fracture. It was reported that reconstructed tomography scans are superior to the plain X- ray films in the emergency setting (4). It was advised that, in case of frontal bone injuries the treating clinician should plan a meticulous differential diagnosis and should go for a 3 dimensional CT scan especially in patients with low Glasgow coma score (4). The reconstructed 3-D format CT scan may provide informative value in comparison to the conventional radiographs in the diagnostic sequence of traumatized patients (4). The information about metopic sutures is enlightening for the medicolegal consultants and forensic experts. Their morphological details are important for the clinician from radiological and surgical point of view. While reading the X-ray/ CT and MRI films, the possibility of the metopic suture should be kept in mind. This will prevent confusion and a wrong diagnosis in emergency situations. Future implications of this subject include studies like iconography with 3D bony reconstruction.

CONCLUSION

The morphological knowledge of the metopic suture is important for the radiologists and neurosurgeons in day-to-day practice. Vertical frontal bone fractures may be easily misdiagnosed with persistent metopic sutures. Hence the doctors should be aware of this anatomical condition while treating the traumatized patient and during surgical intervention including frontal craniotomy. We believe that the present study has provided some important data which will contribute to the scientific literature, providing the anatomical data of metopic suture in the Indian adult population.

ACKNOWLEDGEMENTS

The authors thank all the non-teaching staff members of their department for the valuable help while conducting this study.

REFERENCES

1. Agarwal SK, Malhotra VK, Tewari SP: Incidence of the metopic suture in adult Indian crania. *Acta Anat (Basel)* 105:469-474, 1979
2. Ajmani ML, Mittal RK, Jain SP: Incidence of the metopic suture in adult Nigerian skulls. *J Anat* 137:177-183, 1983
3. Baaten PJ, Haddad M, Abi-Nader K, Abi-Ghosn A, Al-Kutoubi A, Jurjus AR: Incidence of metopism in the Lebanese population. *Clin Anat* 6:148-151, 2003
4. Bademci G, Kendi T, Agalar F: Persistent metopic suture can mimic the skull fractures in the emergency setting? *Neurocirugia* 18:238-240, 2007
5. Bilodi AK, Agrawal BK, Mane S, Kumar A: A study of metopic sutures in human skulls. *Kathmandu Univ Med J* 2:96-99, 2003
6. Breathnach AS: Frazer's anatomy of the human skeleton, 6th edn. London: Churchill Livingstone, 1965:178
7. Bryce TH: Osteology and arthrology. In Quain's elements of anatomy, 11th ed, vol. 4, London: Longmans Green, 1915:177
8. Caffey J: Pediatric X-ray diagnosis, 7th ed, Vol 1. London: Medical Publication Inc, 1978:10-25
9. Castilho SMA, Oda YJ, Santana GDM: Metopism in adult skulls from Southern Brazil. *Int J Morphol* 24:61-66, 2006
10. Chopra SRK: 1957. The cranial suture closure in monkeys. *Proceedings of the Zoological Society of London* 128:67-112
11. del Sol M, Binignat O, Bolini PD, Prates JC: Metopism in Brazilians. *Rev Paul Med* 107:105-107, 1989
12. Eroglu S: The frequency of metopism in Anatolian populations dated from the Neolithic to the first quarter of the 20th century. *Clin Anat* 21: 471-478, 2008
13. Faro C, Chaoui R, Wegrzyn P, Levaillant JM, Benoit B, Nicolaidis KH: Metopic suture in fetuses with Apert syndrome at 22-27 weeks of gestation. *Ultrasound Obstet Gynecol* 27:28-33, 2006
14. Hanihara T, Ishida H: Frequency variations of discrete cranial traits in major human populations. II. Hypostotic variations. *J Anat* 198:707-725, 2001
15. Skrzat J, Walocha J, Zawilinski J: A note on the morphology of the metopic suture in the human skull. *Folia Morphol* 63: 481-484, 2004
16. Jit I, Banga N: Metopism in north-west population of India. *J Anatomical Society of India* 37:45-60, 1988
17. Levine J, Bradley J, Roth D, McCarthy J, Longaker M: Studies in cranial suture biology: Regional duramater determines overlying suture biology. *Plast Reconstr Surg* 101:1441-1447, 1998
18. Manzaranes MC, Goret-Nicaise M, Dhém A: Metopic sutural closure in the human skull. *J Anat* 161:203-215, 1998
19. Pritchard JJ, Scott JH, Girgis FG: The structure and development of cranial and facial sutures. *J Anat* 90:73-86, 1956
20. Romanes GJ: Cunningham Text Book of Anatomy, London: University Press, 1964:134
21. Vu HL, Panchal J, Parker E, Levine N, Francel P: The timing of physiologic closure of the metopic suture: A review of 159 patients using reconstructed 3D CT scans of the craniofacial region. *J Craniofac Surg* 12:527-532, 2001
22. Zumpano PM, Carson BS, Marsh JL, Vanderkolk CA, Richtsmeier JT: Three-dimensional morphological analysis of isolated metopic synostosis. *Anat Rec* 256: 177-188, 1999